



## Male Breast Carcinoma Case Report and Review of Literature

Authors

**Tuhina Mishra, Rajashri Kelkar, Mahendra Navare, Priya Ahire, Milind Ruke,  
Tanvi Shah, Gajanand Vangal**

Department of General Surgery, Grant Government Medical College and Sir Jamshedjee Jeejeebhoy Group of hospitals, Byculla, Mumbai-400008, India

Corresponding Author

**Dr Mahendra Navare**

Grant Government Medical College and Sir J.J. Group of hospitals, Byculla, Mumbai-400008, India

Contact No: 9821159030, Email: [mahendranavare@gmail.com](mailto:mahendranavare@gmail.com)

### Abstract

*The present study reports the case of a 62 year old patient who complained of a swelling over left breast one and half months back. An ulcer developed over the swelling measuring 6×6 cm in size and it was insidious and gradually progressive in nature. The ulcer presented with a slough over left breast with irregular margins and nipple areola complex was not seen. There was negative history of trauma, chest pain, breathlessness, nausea, vomiting, hematemesis, weight loss, breast cancer in family. A biopsy of the ulcer crater which was taken revealed invasive ductal carcinoma. Metastatic workup was done which revealed multifocal lungs liver spleen and brain metastasis with TNM stage 4. Chemotherapy and radiotherapy was started and hormonal sensitivity was checked. The patient was found to be responsive to estrogen and progesterone receptor and had negative HER 2.*

*As with many other rare “orphan” diseases, male breast cancer is understudied. The rarity of the disease precludes prospective randomized clinical trials. In addition, few researchers and minimal funding have focused on breast cancer in men, but further work is clearly needed to better understand this disease. It shares many similarities with breast cancer in women; yet some clear differences have emerged. In this article, the latest information on the epidemiology, biology, and treatment of male breast cancer is reviewed.*

**Keywords:** male breast cancer; epidemiology; review.

### Introduction

Breast cancer in men is rare, and it accounts for about 1% of all malignant breast neoplasm cases<sup>(1,2)</sup>. The estimated incidence is 1 case for each 100,000 men<sup>(1,2)</sup>. Among the histologic types, invasive ductal carcinoma is the most prevalent breast cancer in males, with an incidence varying from 65 to 95%<sup>(2,3)</sup>. Male breast cancer has unimodal age-frequency

distribution with a peak incidence at 71 years old. Conversely, female breast cancer has a bimodal age-frequency distribution with early-onset and late-onset peak incidences at 52 and 72 years old, respectively<sup>(4)</sup>. We present the case of a 62 year old male patient who presented with metastatic disease 6 years after the initial mastectomy. We also present a literature review of incidence, histological patterns, receptor status, patterns of

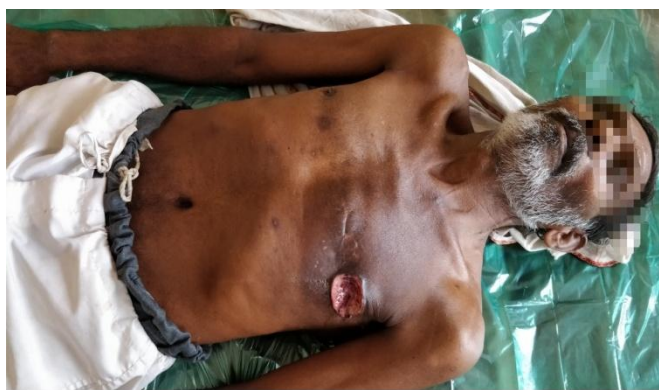metastasis & prognosis of male patients with breast cancer.

### Case Study

A 62 year old patient came with complaint of an ulcer over the left breast since 4 to 5 months. The ulcer was spontaneous in onset & gradually progressing in size. There was history of serosanguinous discharge from the ulcer. He gave a past history of undergoing a surgery over the same site 6 years back for a swelling that he had noticed following a trauma. He did not receive any adjuvant treatment at that time & presented 6 years later with above complaints. There was no family history of breast or ovarian cancer. He also did not give any history of bone pains, fractures, jaundice, abdominal distension, convulsions or focal neurological deficits.

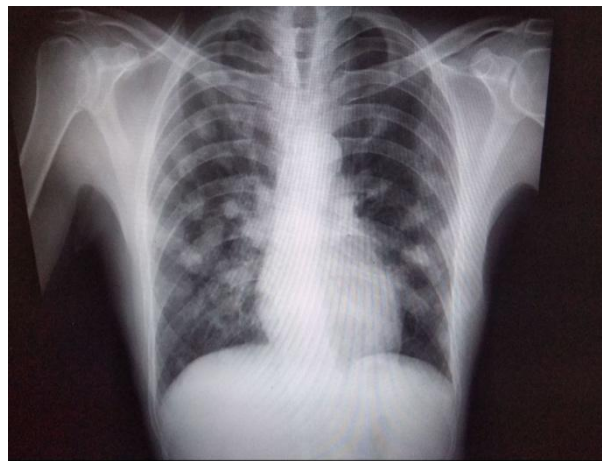
On examination he had stable vitals, ECOG score of 0 & no evidence of cachexia.

There was a 5 x 4 x 4 cm ulcer over the left breast overlying the scar of previous mastectomy. The ulcer had irregular margins, indurated edges, slough over the floor with serosanguinous non foul smelling discharge & was fixed to the chest wall. He had multiple hard, immobile left axillary palpable lymph nodes.



**Figure 1: Ulcer on Left Breast**

An edge biopsy of the ulcer revealed high grade invasive ductal carcinoma. Immunohistochemistry was positive of estrogen & progesterone receptors & negative for HER-2-neu receptors. Metastatic workup was done which revealed multifocal lung, liver, spleen and brain metastasis.



**Figure 2: X-Ray Showing Metastasis**

He was started on chemotherapy with palliative breast irradiation & Tamoxifen. The patient tolerated the treatment well with ECOG score persistently 0 & stable disease.

### Discussion (Literature Review)

Since the incidence of breast cancer is low, no randomized trials have been conducted and most information on male breast cancer has been collected from retrospective studies spanning several decades, and treatment recommendations have been extrapolated from results of trials in female patients. Differences between male and female breast carcinoma have been noted; male breast carcinoma has a tendency to present at higher clinical stages and with more lymph node metastases. The incidence increases exponentially with age.<sup>(6)</sup>

**Table 1: Incidence of Male Breast Cancers in Different Regions**

Countries	Incidence of Breast Cancer
Tanzania <sup>(5)</sup>	6%
Eastern India <sup>(8)</sup>	0.6%
Pakistan <sup>(9)</sup>	4.6%
Western Countries <sup>(1)</sup>	1%

The etiology of male breast carcinoma is unclear, but hormonal levels may play a role in the development of this disease. Testicular abnormalities such as undescended testes, congenital inguinal hernia, orchidectomy, orchitis, and infertility have been consistently associated with elevations in breast cancer risk.<sup>[9]</sup> Klinefelter's syndrome, in which patients

carry XXY chromosomes, may be present in 3%–7% of men with breast cancer, giving males with Klinefelter's syndrome a 50-fold greater risk over the general male population.<sup>[9]</sup> Men with a family history of breast cancer in a female relative have 2.5 times the odds of developing breast cancer.<sup>[11]</sup> Prior radiation as in case of mantle field for Hodgkin lymphoma increases the risk of a subsequent breast cancer.<sup>[9]</sup> Alcohol-use, liver disease, obesity, electromagnetic field radiation, and diet have all been proposed as risk factors, but findings have been inconsistent across studies. Approximately 15%–20% of men with breast cancer report a family history of breast or ovarian cancer. It is estimated that approximately 10% of men with breast cancer have a genetic predisposition, and BRCA2 is the most clearly associated genemutation.<sup>[12]</sup> BRCA1 mutation is also associated with PTEN, P53, and CHEK2<sup>[13-16]</sup> Among male BRCA2 mutation carriers, the estimated lifetime risk of breast cancer is 5%–10% compared with a general population risk of 0.1%.<sup>[17]</sup> The lifetime risk of MBC with BRCA1 mutations is approximately 1%–5%.<sup>[18]</sup> CHEK2 1100 del C increases the risk of both male and female breast cancer, particularly among individuals with a family history and a CHEK2 mutation.<sup>[19]</sup> At all stages, black men have a higher incidence than white men. Black men also tend to have poorer prognostic features such as advanced-stage disease, larger tumor sizes, more nodal involvement, and higher tumor grade, compared with their white counterparts.<sup>[20]</sup>

The most common presenting symptoms in male breast carcinoma patients are a painless subareolar lump, nipple retraction, and bleeding from the nipple.<sup>[21-23]</sup> Nipple is involved in about 50% of cases at presentation.<sup>[24]</sup> Due to lack of awareness, >40% of men present with stage III or IV disease.<sup>[25]</sup>

Biopsy is required for definitive diagnosis in most breast cancer cases in men. Fine-needle aspiration (FNA) biopsy of the male breast has high

sensitivity and high specificity, and with almost 100% positive predictive value for the diagnosis of malignancy.<sup>[26-29]</sup> FNA biopsy allows accurate diagnosis in many medical changes that occur in the male breast. However, this technique is less helpful with ductal carcinoma in situ (DCIS), especially in lesions that are cystic, such as papillary DCIS, which has been described as having a strong cystic component.<sup>[30]</sup> Core needle biopsy or FNA biopsy should be used more often because these procedures can help to avoid unnecessary surgery and may help in the planning of any surgeries for cancer cases.<sup>[29]</sup>

<sup>1</sup>Histopathologically, the majority of tumors are invasive ductal carcinoma (85%–95%), followed by DCIS (5%–10%). Invasive papillary carcinoma is more common in males than in females, accounting for approximately 2%–4% of breast cancers in men compared with up to 1% in women.<sup>[2,3]</sup>

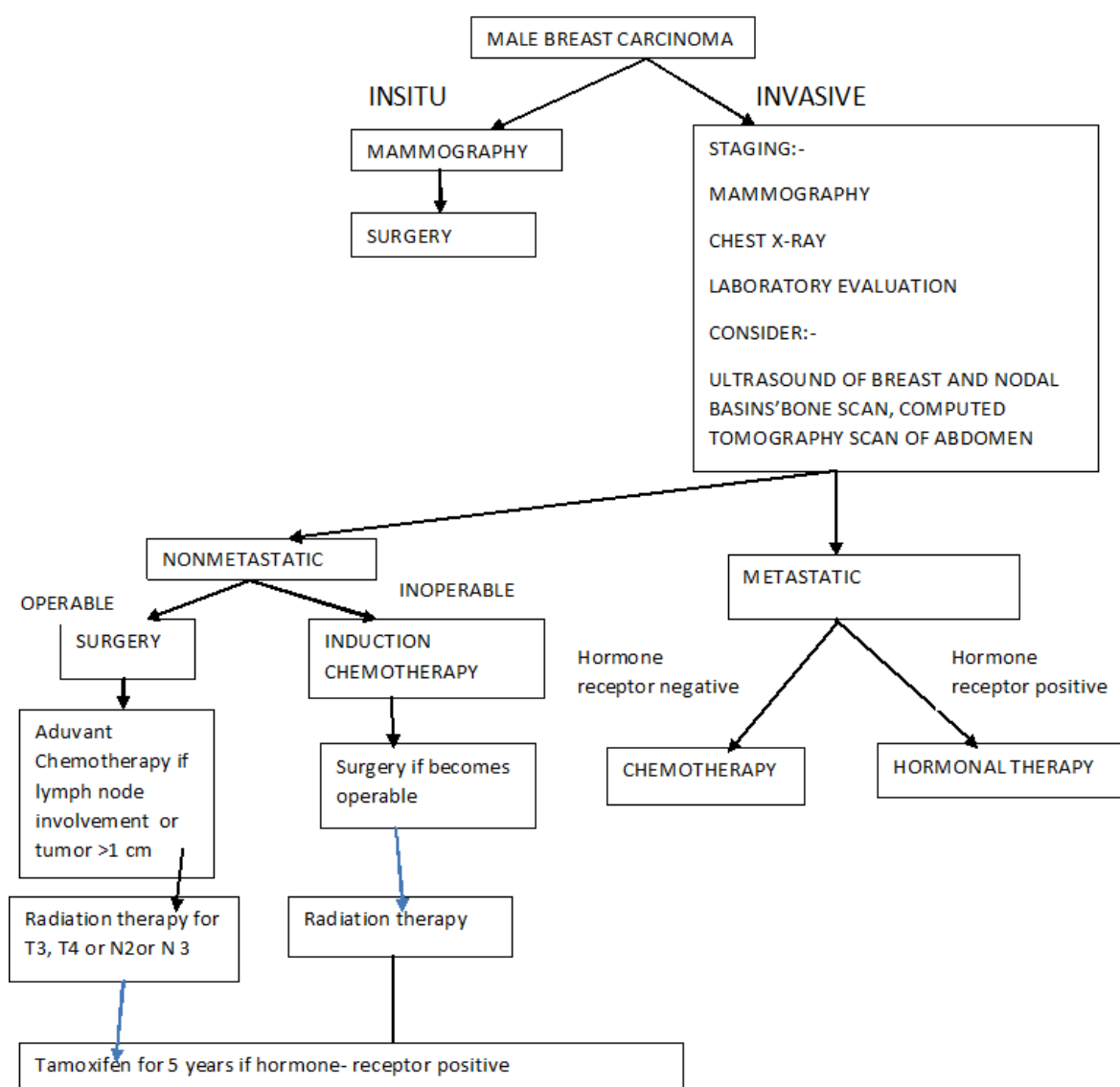
**Table 2:** Histopathological types of Male Breast Carcinoma

Histology	Percentage(%)
Invasive ductal	85-95
ductal carcinoma in situ	5-10
invasive papillary	2
medullary	2
mucinous	1
paget's	1
lobular	1

Estrogen receptors are expressed in 90% of male breast carcinomas, a higher proportion than in women and up to 96% are progesterone receptor positive.<sup>[31]</sup> Human epidermal growth factor receptor 2 over expression has been reported in 16%, on average slightly lower than in females but its effects on prognosis are unclear.<sup>[31]</sup> Hill et al. reported an overall 5-year and 10-year survival rate in patients with localized disease to 86% and 64%, respectively. With positive lymph nodes, the 5 and 10-year survival rate decreased to 73% and 50%, respectively. The prognosis is worse if four or more lymph nodes are involved (10-year survival drops to 14%). The old age, comorbidity at presentation, and shorter life expectancy in men also affect prognosis.<sup>[32]</sup>

Traditionally radical mastectomy (HALSTED) was the reference treatment in male breast cancer due to the frequent invasion of the pectoral major muscle. Increasingly, it leaves space for modified radical mastectomy (Patey and modified Patey) that gives the same results with less postoperative complications<sup>[33]</sup>. Radical mastectomy (HALSTED) and modified radical mastectomy (PATEY) represent together, more than 70% of surgical procedures<sup>[34]</sup>. Nowadays, modified radical mastectomy is the standard treatment<sup>[33]</sup>.

However, the surgery of male breast cancer has become less and less invasive. The most recent studies mention lumpectomy and sentinel lymph node technique which give the same therapeutic results as radical surgery for tumors with sizes T1 and T2<sup>[34,35]</sup>. The sentinel lymph node technique would enable like in women, reduce morbidity related to axillary dissection for small tumors of less than 2.5 cm<sup>[36,37]</sup>.



**Figure:-3** Treatment Algorithm for Male Breast Carcinoma

Male breast carcinoma though rare exists. Efforts to increase awareness among physicians and patients would prevent it from spreading to other parts of the body. Risk factors include family history of breast carcinoma, klinefelter's

syndrome, prior history of exposure to radiation. The role of chemotherapy and adjuvant hormonal treatment deserves more researches.

**Source of Grant:** None

## References

1. Fentiman IS, Fourquet A, Hortobagyi GN: Male breast cancer. Lancet 2006, 367:595-604.
2. Gennari R, Curigliano G, Jereczek-Fossa BA, Zurrida S, Renne G, Intra M, Galimberti V, Luini A, Orecchia R, Viale G, Goldhirsch A, Veronesi U: Male breast cancer: a special therapeutic problem. Int J Oncol 2004, 24:663-670.
3. Giordano SH, Cohen DS, Buzdar AU, Perkins G, Hortobagyi GN: Breast carcinoma in men: a population-based study. Cancer 2004, 101:51-57.
4. Anderson WF, Althuis MD, Brinton LA, Devesa SS: Is male breast cancer similar or different than female breast cancer? Breast Cancer Res Treat 2004, 83:77-86.
5. Sasco AJ, Lowenfels AB, Pasker DE, Jong P. Review article: epidemiology of male breast cancer. Int J Cancer. 1993;53:538-549.]
6. Amir H, Makwaya CK, Moshiro C, Kwesigabo G. Carcinoma of the male breast. A sexually transmitted disease? East Afr Med J. 1996;73:187-190.
7. Mitra D, Manna A, Sikdar SK, Sur PK. A clinicopathological study and its prognostic implication in male breast carcinoma. JIMA. 2007;105:681-683.
8. Sharif MA, Mamoon N, Arif A, Mushtaq S, Khadim MT. Histological and immunohistochemical study of male breast carcinoma in Northern Pakistan. J Pak Med Assoc. 2009;59:67-71.
9. Sasco AJ, Lowenfels AB, Pasker-de Jong P. Review article: Epidemiology of male breast cancer. A meta-analysis of published case-control studies and discussion of selected aetiological factors. Int J Cancer 1993;53:538-49.
10. Hultborn R, Hanson C, Köpf I, Verbiené I, Warnhammar E, Weimarck A. Prevalence of Klinefelter's syndrome in male breast cancer patients. Anticancer Res 1997;17:4293-7.
11. Rosenblatt KA, Thomas DB, McTiernan A, Austin MA, Stalsberg H, Stemhagen A, et al. Breast cancer in men: Aspects of familial aggregation. J Natl Cancer Inst 1991;83:849-54.
12. Couch FJ, Farid LM, DeShano ML, Tavtigian SV, Calzone K, Campeau L, et al. BRCA2 germline mutations in male breast cancer cases and breast cancer families. Nat Genet 1996;13:123-5.
13. Brose MS, Rebbeck TR, Calzone KA, Stopfer JE, Nathanson KL, Weber BL. Cancer risk estimates for BRCA1 mutation carriers identified in a risk evaluation program. J Natl Cancer Inst 2002;94:1365-72.
14. Anelli A, Anelli TF, Youngson B, Rosen PP, Borgen PI. Mutations of the p53 gene in male breast cancer. Cancer 1995; 75:2233-8.
15. Fackenthal JD, Marsh DJ, Richardson AL, Cummings SA, Eng C, Robinson BG, et al. Male breast cancer in Cowden syndrome patients with germline PTEN mutations. J Med Genet 2001;38:159-64.
16. Meijers-Heijboer H, van den Ouweland A, Klijn J, Wasielewski M, de Snoo A, Oldenburg R, et al. Low-penetrance susceptibility to breast cancer due to CHEK2(\*) 1100delC in noncarriers of BRCA1 or BRCA2 mutations. Nat Genet 2002;31:55-9.
17. Breast Cancer Linkage Consortium. Cancer risks in BRCA2 mutation carriers. J Natl Cancer Inst 1999;91:1310-6.
18. Tai YC, Domchek S, Parmigiani G, Chen S. Breast cancer risk among male BRCA1 and BRCA2 mutation carriers. J Natl Cancer Inst 2007;99:1811-4.
19. CHEK Breast Cancer Case-Control Consortium. CHEK2\* 1100delC and susceptibility to breast cancer: A collaborative analysis involving 10,860

- breast cancer cases and 9,065 controls from 10 studies. *Am J Hum Genet* 2004;74:1175-82.
20. Anderson WF, Althuis MD, Brinton LA, Devesa SS. Is male breast cancer similar or different than female breast cancer? *Breast Cancer Res Treat* 2004;83:77-86. *Roentgenol* 1993;160:267-70.
  21. El-Gazayerli MM, Abdel-Aziz AS. On bilharziasis and male breast cancer in Egypt: A preliminary report and review of the literature. *Br J Cancer* 1963;17:566-71.
  22. Giordano SH, Buzdar AU, Hortobagyi GN. Breast cancer in men. *Ann Intern Med* 2002;137:678-87.
  23. Bloom KJ, Govil H, Gattuso P, Reddy V, Francescatti D. Status of HER-2 in male and female breast carcinoma. *Am J Surg* 2001;182:389-92.
  24. Contractor KB, Kaur K, Rodrigues GS, Kulkarni DM, Singhal H. Male breast cancer: Is the scenario changing. *World J SurgOncol* 2008;6:58.
  25. Shukla NK, Seenu V, Goel AK, Raina V, Rath GK, Singh R, et al. Male breast cancer: A retrospective study from a regional cancer center in Northern India. *J SurgOncol* 1996;61:143-8.
  26. Joshi MG, Lee AK, Loda M, Camus MG, Pedersen C, Heatley GJ, et al. Male breast carcinoma: An evaluation of prognostic factors contributing to a poorer outcome. *Cancer* 1996;77:490-8.
  27. Rosen DG, Laucirica R, Verstovsek G. Fine needle aspiration of male breast lesions. *ActaCytol* 2009;53:369-74.
  28. Lilleng R, Paksoy N, Vural G, Langmark F, Hagmar B. Assessment of fine needle aspiration cytology and histopathology for diagnosing male breast masses. *Acta Cytol* 1995;39:877-81.
  29. Westenend PJ. Core needle biopsy in male breast lesions. *J ClinPathol* 2003;56:863-5.
  30. Yang WT, Whitman GJ, Yuen EH, Tse GM, Stelling CB. Sonographic features of primary breast cancer in men. *AJR Am J Roentgenol* 2001;176:413-6
  31. Rayson D, Erlichman C, Suman VJ, Roche PC, Wold LE, Ingle JN, et al. Molecular markers in male breast carcinoma. *Cancer* 1998;83:1947-55.
  32. Hill A, Yagmur Y, Tran KN, Bolton JS, Robson M, Borgen PI. Localised male breast carcinoma and family history. An analysis of 142 patients. *Cancer* 1999;86:821-5.
  33. Zhou FF, Xia LP, Guo GF, Wang X, Yuan ZY, Zhang B, Wang F. Changes in therapeutic strategies in Chinese male patients with breast cancer: 40 years of experience in a single institute. *Breast*. 2010;19:450–5.
  34. Darkeh MHSE, Azavedo E. Male breast cancer clinical features, risk factors, and current diagnostic and therapeutic approaches. *Int J Clin Med*. 2014;5:1068–86.
  35. Akkamma R, Heejung B, Karen K, Dattatreyyudu N. Breast cancer in men: prognostic factors treatment patterns and outcome. *Am J Mens Health*. 2011;6(1):51–8.
  36. Taber KAJ, Morisy LR, Osbahr AJ, Dickinson BD. Male breast cancer: risk factors, diagnosis, and management (review). *Oncol Rep*. 2010;24(5):1115–20.
  37. Adamu A, Yahaya U, Adamu A, Iliyasu M. Management and outcomes of male breast cancer in Zaria, Nigeria. *Int J Breast Cancer*. 2012;1:1–6.