



Quadruplet Pregnancy Following Spontaneous Conception: A Rare Case Report

Authors

Veena Meena¹, Khuteta Sushila², Amarawatin Kurre¹, Kalpana Bariha¹,
Meena Shyam³

¹MS Residents in Obstetrics & Gynaecology, SMS MC Jaipur, Rajasthan

²Senior Professor in Obstetrics & Gynaecology SMS MC Jaipur, Rajasthan

³MD-Anaesthesiologist

ABSTRACT

Higher order (triplet or more) multiple pregnancies occur when more than two fetuses are present in the uterus at the same time. Quadruplets are a set of four offspring born at one birth which can be fraternal (multizygotic), identical (monozygotic) or a combination of both. Multizygotic quadruplets occur from fertilisation of four different sets of ovum and sperm. Monozygotic multiples are the result of a fertilized egg that splits into two or more embryos. Multizygotic quadruplets can be all male, all female, or a combination of both while monozygotic quadruplets will always be of the same gender. Here we present a case of 26-year-old G2A1L0 with previous history of one spontaneous abortion at 8 wk of gestation. After evaluation, she was found to carry three live foetuses with an IUFD. She was managed conservatively till 35 wk of gestation with regular monitoring of coagulation parameters. Elective caesarean section was done at 35 wk; two male, one female live babies and one IUFD male baby were delivered. This case is unique due to the fact that our patient conceived a multizygotic quadruplet pregnancy spontaneously after an abortion. One fetus died in utero and the pregnancy continued successfully resulting in 3 live born healthy babies.

Keywords: Multiple gestations, Quadriamniotic quadrichorionic placenta, intrauterine death.

Introduction

Multiple pregnancies and in particular higher order multiple pregnancies (triplets, quadruplets, quintuplets) are high risk pregnancies with associated increases in maternal, fetal and neonatal morbidity and mortality. Their frequency has been on the increase in the past two decades, mostly as a result of ovulation induction and assisted reproductive techniques for infertile couples.⁽¹⁾ The incidence of quadruplet pregnancy had traditionally been put at 1: 80³ which translates into 1: 512,010 pregnancies,⁽²⁾ although

this may be higher in a place like south western Nigeria where twinning rates can be as high as 1: 22 births.⁽³⁾ Higher order multiple pregnancies could be monozygotic, multizygotic or a combination of the two.⁽⁴⁾ Preterm labour and delivery appears to be the commonest maternal complication, with the mean gestational age at delivery being 31 weeks in quadruplet pregnancies.^(1,2) Term delivery is rare occurring in less than 3% of such pregnancies.

Case Report

A 25-year-old G2A1L0 was admitted to our hospital at 28 wk gestation with chief complaint of shortness of breath and lower abdominal discomfort of one week duration. She had been married for three years with previous one spontaneous abortion. She was diagnosed as a case of quadruplet pregnancy by ultrasound in first trimester at 11 wk gestation in the present pregnancy. Folic acid tablets were taken in the first trimester. In view of previous one spontaneous abortion at 8 weeks of gestation, not followed by evacuation. There was no history of ovulation induction or use of assisted reproductive techniques. There was history of prophylactic cervical cerclage by Mc-Donald operation at 22 weeks of gestation. Her previous menstrual cycles were regular and her marriage was a non-consanguineous one. There was no other relevant past and family history. On general examination, our patient was conscious, oriented and afebrile. She was pale with demonstrable pedal edema. Respiratory and cardiovascular system examinations were found to be normal. On per abdomen examination uterus was over-distended with multiple palpable fetal parts. Two fetal heart sounds were distinctly audible on auscultation. Vaginal examination revealed cervix long, soft posterior with os closed. On ultrasound examination at the time of admission, she was diagnosed to have one intrauterine death with three live fetuses. She was on hematinics, folic acid, calcium. Patient and attendees were counseled regarding risks of continuation/termination of pregnancy, outcome of fetus with respect to short term and long term effects were considered. After obtaining their consent, she was managed conservatively till 35 wk gestation with regular monitoring of coagulation parameters. She received 2 doses of betamethasone at 30 wk gestation to improve fetal outcome and one unit of whole blood. Elective caesarean section was done at 35 wk gestation and quadruplets were delivered, among which 3 were live two male, one female babies (were admitted

to Neonatal Intensive Care Unit and discharged after 4 days) and one male dead fetus [Fig-1]. The birth weight of the two male and one female baby were 1700 gm, 1500 gm and 1350 gm respectively. The male still born weighed 900 gm. Placenta was found to be quadrichorionic quadriamniotic [Fig-2,3]. Intra operative and postoperative period were uneventful. Patient was discharged from hospital with three live babies on seventh postoperative day.

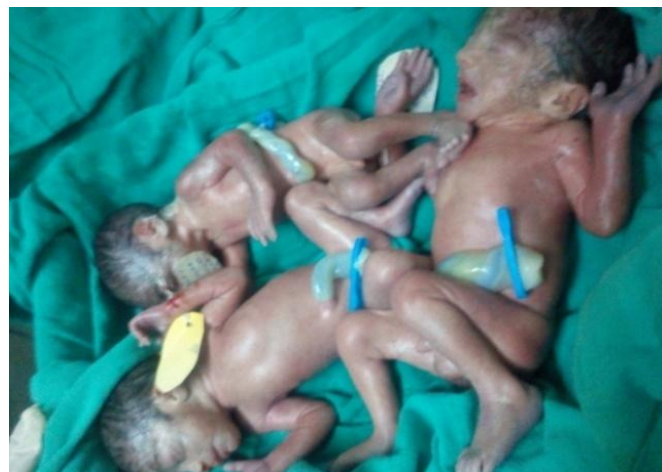

Figure 1-Three live babies of quadruplet pregnancy (two male and one female)

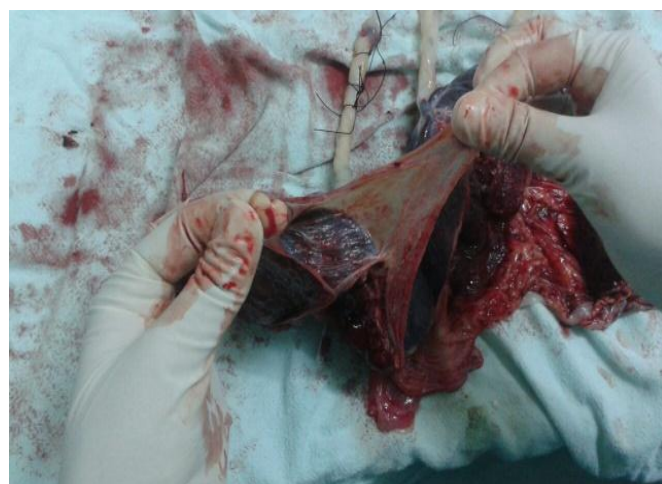

Figure 2- Quadrichorionic quadriamniotic placenta

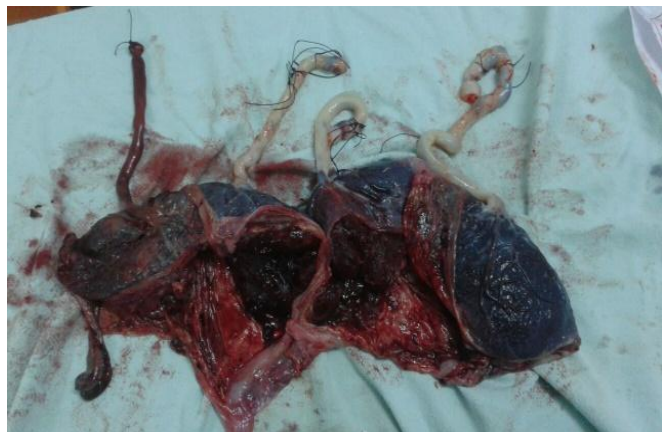


Figure 3 - Quadrichorionic quadramniotic placenta (fetal side)

Discussion

Higher order (triplet or more) multiple pregnancies occur when more than two fetuses are present in the uterus at the same time. Higher order multiple pregnancies are increasingly being associated with assisted conception techniques like ovulation induction and in-vitro- fertilization (IVF) techniques.^(1,5,,3) Spontaneous quadruplet pregnancy is very uncommon with an incidence rate of 1 in 512000 to 1 in 677, 000 births ^[6]. Though ovulation induction and ART procedures contribute to the bulk of cases in the present arena, cases of quadruplet pregnancies have been reported following the cessation of Clomiphene citrate for ovulation induction, the so- called “sustained effect”.^[7] The incidence of multiple pregnancies with clomiphene is between 5-10%.⁽⁸⁾ In monochorionic pregnancies, death of one twin confers the risk of cerebral damage in co-twin of about 25% and of death in a further 25%. Disseminated Intravascular Coagulation is a major maternal complication especially if the time interval from intrauterine death to delivery exceeded 5 wk ^[9]. The management of higher order multiple pregnancies entails early diagnosis, clinical monitoring, early institution of bed rest (home or hospital) and elective caesarean section delivery ⁽⁵⁾. Successful outcome is better with a combined obstetric- neonatal approach and the experience of a perinatal unit. Combination tocolytic therapy to treat preterm contractions and insertion of a cervical cerclage may occasionally

be necessary. Nnadi D et al., ^[10] reported a case of spontaneous monochorionic tetra-amniotic quadruplet pregnancy by natural conception following a 12-year history of unexplained primary infertility. Elective caesarean section was done at 37 wk and a set of monochorionic tetra-amniotic quadruplets (all females) were delivered. Vikranth U et al., ^[11] reported a case of quadruplet pregnancy following ovulation induction with gonadotrophin and human chorionic gonadotrophin. Elective caesarean section was done at 35 wk of gestation and a set of quadruplets (three females and 1 male) were delivered. All the three female babies had no obvious congenital anomalies whereas the male baby had features of asymmetric intrauterine growth restriction with vesico-rectal fistula. In a study by A L Adegbite et al., in TC(trichorionic) quadruplets, only one pregnancy was complicated by fetofetal transfusion syndrome. The patient went into spontaneous labor soon after the diagnosis at 23 wk of gestation and all four infants died immediately after birth ^[12]. As regards the neonatal outcome, TC quadruplets had significantly higher risks of respiratory distress syndrome (RDS), anemia and IVH compared to QC (quadrichorionic) infants. Long-term outcome in terms of chronic lung disease was also higher in TC than those of QC infants ^[12]. A thorough neonatal evaluation is indicated for the surviving fetuses to detect CNS, renal, circulatory and cutaneous defects. Investigations may include high resolution ultrasonography of brain, CT, MRI and renal function tests. Long term follow up is mandatory ^[13]. A case series by HHN Woo et al., concluded that, single fetal death in multiple pregnancies should be managed in a tertiary referral centre, where intensive fetal surveillance and adequate neonatal support are available ^[14]. A multidisciplinary approach should be adopted. The preferred method of delivery of quadruplet pregnancies is elective Caesarean section. This is because of increased risk of fetal malpresentations and difficult intrapartum fetal monitoring associated with the condition.

Conclusion

Conservative management is preferred in case of single fetal demise in multiple gestations. However the risk of keeping surviving twin in a hostile intrauterine environment must be weighed against the risk of preterm delivery. Multifetal gestation comprises a high risk pregnancy and proper antenatal and intrapartum care results in a successful maternal and fetal outcome as seen in our case.

Foot Notes

There is no conflict of interest in this rare case report. Institutional ethical approval and consent were also taken for this study.

References

1. Fisk NM. Higher order multiples. In: Keith Edmonds (ed). Dewhursts textbook of obstetrics and gynaecology for post graduates. Blackwell, Edinburgh.1999; 306.
2. Pernoll ML, Benson RC. Multiple pregnancy. In: Decheney AH (ed). Current obstetrics and gynaecologic diagnosis and treatment. Appleton and Lange, Connecticut. 1994; 357-367.
3. Marinho AO, Ilesanmi AO, Ladele AO, Asuni OH, Omigbodun AO, Oyejide CO. A fall in the rate of multiple births in Ibadan and Igbo-Ora Nigeria. Acta Genet Med Gemellol 1986; 35: 201-204.
4. Nkyekyer K. Multiple pregnancy. In: Kwawukume EY, Emuveyan EE (eds). Comprehensive obstetrics in the tropics. Asante and Hittscher, Accra. 2002; 162-172.
5. Spellacy WN. Multiple pregnancies (quadruplets or more). In: Scott JR (ed). Danforths obstetrics and gynaecology. Lippincott Williams & Wilkins, Baltimore. 2000; 293-300.
6. Goldman GA, Dicker D, Peleg D, Goldman JA. Is elective cerclage justified in the management of triplet and quadruplet pregnancy? Aust NZL J Obstet Gynaecol. 1989;29:9-11.
7. Doyle P. The outcome of multiple pregnancies. [4] Hum Reprod. 1996;11:110-20.
8. Hull MGR. Ovulation failure and induction. Clin Obstet Gynecol 8; 753.
9. Harshini V, Geethanjali, Vijaya R, Prajna. Outcome in twin pregnancy with intrauterine death of first twin- A case report. Int J Med Health Sci. 2012;1(4):7275.
10. Nnadi D, Ibrahim A, Nwobodo E. Spontaneous monochorionic tetra-amniotic quadruplet pregnancy at term. J Basic Clin Reprod Sci. 2013;2:57-59.
11. Vikranth U, Borkar NV, Desai SK, Kania P, Rangoonwala NH. A Quadruplet pregnancy. J Obstet Gynecol India. 2007;57(5):439-41.
12. Adegbite AL, Ward BS, Bajoria R. Perinatal outcome of quadruplet pregnancies in relation to chorionicity. Journal of Perinatology. 2007;27:15–21.
13. D' Alton ME, Newton ER, Cetrulo CL. Intrauterine fetal demise in multiple gestations. Acta Genet Med Gemellol. 1984;33:43-49.
14. HHN Woo, SY Sin, LCH Tang. Single fetal death in twin pregnancies: review of the maternal and neonatal outcomes and management. HKMJ. 2000;6:293300.