



Uterine Myoma, Epidemiology, Pathophysiologic, Reproductive, Clinical and Therapeutic

Authors

Vargas-Hernández Víctor Manuel, Tovar-Rodríguez José María, Agustín I Rodríguez Blas, Vargas-Aguilar Víctor Manuel

Juárez Hospital of Mexico, Mexicocity, Mexico

Corresponding Author

Víctor Manuel Vargas-Hernández.

Insurgentes Sur 605-1403, c.p. 03810 Nápoles, Mexicocity, Mexico.

Email: vvargashernandez@yahoo.com.mx.

ABSTRACT

The Uterine leiomyomas are benign smooth muscle tumors of slow growth, most patients are asymptomatic or discovered during a routine gynecological examination. Clinical manifestations occur in 20-40% with abnormal uterine bleeding, chronic pelvic pain, pelvic heaviness and occasionally reproductive alterations related to the size and location of leiomyoma's. The medical management is to improve symptoms or facilitate surgery, particularly if conservative avoiding the complications associated with surgery. Technological advances in minimally invasive surgery, interventional imagenological, new drugs and a better understanding of tumor biology of leiomyoma's have replaced the traditional treatment hysterectomy. The uterine leiomyoma's commonly found in women of reproductive age, which most do not require treatment because of their kindness and only when it interferes with their quality of life should be treated individually.

Keywords: leiomyoma's, genetics, reproduction, pregnancy, magnetic resonance imaging, ultrasound, laparoscopy, hysteroscopy, myomectomy, hysterectomy, minimal invasive surgery, hormone therapy, embolization.

INTRODUCTION

Leiomyomas (LM) are benign uterine monoclonal histopathologically arise from smooth muscle proliferation and connective tissue of the uterus, are slow-growing and malignant degeneration is less than 1.0% and as low as 0.2%. Despite the fact that the cause is unknown, there is evidence that estrogens and progestins promote their growth, as they rarely develop before menarche and menopause subside after considering that depend on hormones and are a public health problem^[1-3].

LM The worldwide prevalence varies from 5-21%, increases with age, 1.8% in women aged 20-

29 years and 14.1% older than 40 years, 60% develop in women of reproductive age and 80 % lifetime predominantly in blacks, in women 35 to 49 years of age, medical history and ultrasound (US) diagnosis, the incidence is 60%, and African American women, increases to 80% at age 50 , while Caucasian women, the incidence was 40% at the age of 35 years and 70% at 50 years of age is commonly diagnosed in 25% to 30% in women older than 35 years and 77% reported in autopsies of women killed by various causes. Besides race, other risk factors (RF) are early menarche, familial predisposition and overweight and

multiparity and smoking protect against its development^[2,3].

CLINICAL ASPECTS LEIOMYOMAS

Worldwide, the average age at diagnosis, varies from 34.8 ± 7.6 . The frequency of abnormal uterine bleeding (HUA) in women with a diagnosis of LM is 59.8% compared to 37.4% women without diagnosis ($p < 0.001$)^[2]

Most women with LM are asymptomatic and often go undiagnosed or are discovered during a routine gynecological examination^[1,2]. Women diagnosed with LM pezantes often experience pelvic chronic pelvic pain compared with women without a diagnosis of LM (32.6% and 14.5% vs 15.0% and 2.9%) ($p < 0.001$). Symptomatic women often complain HUA, menorrhagia type, intense and prolonged bleeding, urinary and intestinal discomfort, dyspareunia, which negatively affect the sexual life, his work and family relationship^[2,4,5]; 10% are associated with infertility and 1-3% are only cause of this. These symptoms are related to the size and location of the LM, although women reported in LM comparable size to 8 weeks of gestation under clinical supervision were unchanged (77%)^[2].

UTERINE AND REPRODUCTIVE CAPACITY LEIMYOMAS

There are many controversies related to reproduction in women with LM. In particular those infertile women with unexplained infertility, the LM is often considered as a cause of this, affecting the normal transport of gametes or embryos through the genital tract, altering the normal development of pregnancy and embryo implantation in the uterus. The submucosal and intramural LM result in distortion of the uterine cavity to prevent implantation of the embryo with this loss^[2,6-9], but in women with myomectomy and were performed in vitro fertilization (IVF) pregnancy rate was similar to women without LM, indicating that the LM does not affect fertility and surgery in most of these is not indicated, when the LM intramural do not distort the endometrial cavity is controversial reproductive role and use of

assisted reproductive techniques (ART)^[10]. Several studies attempt to clarify the role of LM in dealing with ART^[11,12], but do not take into account important factors such as size, location, age, diagnosis, number of LM confounding affecting the evidence on the impact of LM on the reproductive function, creating controversy over the treatment recommended in these women to improve their fertility^[13].

The submucosal and intramural LM distorting the uterine cavity has a negative impact on results in the ART and these tumors affect the implementation of 33-70% and decrease the clinical pregnancy rate 67-70% compared with infertile patients without LM; clinical pregnancy rate and live birth rate is reduced 70% in women with submucosal LM and women under management of ART with these, have a worse prognosis compared with women without LM, including lower clinical pregnancy rate, implantation and newborns alive^[10,11], but intramural LM impact and submucosal during handling with ART, which distort the uterine cavity altered reproductive capability^[11] unlike not distort LM intramural uterine cavity are conflicting reports, in LM intramural (10 to 50mm) and subserosal when evaluated with hysteroscopy to exclude any distortion of the uterine cavity intramural LM suspect that do not affect pregnancy rate, embryo implantation or ART cycles (OR: 1.41 (95% CI 0.67 to 2.98), 1.75 (95% CI: 0.90 to 3.39), 1.36 (95% CI 0.58 - 3.15), respectively^[14-16], in addition, 3 of each 25 genes associated with implantation are expressed abnormally in women with LM intramurales^[10], other studies suggest negative effect on ART in patients with LM not affecting intramural uterine cavity, with reduced implantation and pregnancy rate (implementation: 11, 9% vs 20.2%, $p = 0.018$; pregnancy: 15.1% vs 28.3%, $p = 0.003$) also reported reduced clinical pregnancy in patients with LM > 4cm (29% vs 52%, $p = 0.025$). compared with women without LM, demonstrating a negative impact of these when using ART, in patients with and without LM average size 2.1 ± 0.8 3.7 ± 1.2 cm, to correct the

age and average number of embryos transferred for implantation were lower (OR 0.62, 95% CI 0.48 to 0.80), clinical pregnancy (OR 0.66, 95% CI 0.48 to 0.89) and live births (OR 0.69, 95% CI 0.50-0.95) [13-16] showing a negative impact on the management of the LM ART who have not distort the uterine cavity, primarily over 3cm large, affecting implantation [13-16].

Ultrasonography in the management, evaluation, diagnosis and treatment of infertility, increases the incidence of diagnosed LM 3cm mainly over not affect the uterine cavity, but adversely affect the implantation rate and clinical pregnancy compared with women for ART patients without LM; myomectomy improves outcomes of ART. The LM subserosal affecting more than 50% of the total volume of the uterine serosa, do not affect implantation and clinical pregnancy (OR 1.0, 95% CI 0.8-1.2) or delivery (OR 0.9, 95% CI 0.7 to 1.1) [10,11].

PATHOPHYSIOLOGY OF LEIOMYOMAS

The molecular etiology of LM being understood. Risk factors include: family-inherited history,

black race, age, nulliparity and obesity [4,17]. The growth and regression vary between LM; rapid growth during the reproductive age is not associated with increased risk of malignancy in 0.23% develops some type of uterine sarcoma and 0.27% leiomyosarcoma. Growth is impossible to predict, although the increased volume in 6-12 months of 9% with wide variation in size, from a 25% to 138% growth in one year. During pregnancy most no change in the size even 80% decrease in size spontaneously at 5 months postpartum, the changes that occur in the uterus and naturally during reproductive age, explain a protective effect of the parity on the risk of developing them. The growth rate is also related to race, white women have lower growth rate during perimenopause, while African-American women is higher [1-3].

The heterogeneity of leiomyomas is caused by biological differences and their growth and development has long been associated with sex hormones estrogen and mainly various factors see figure 1.

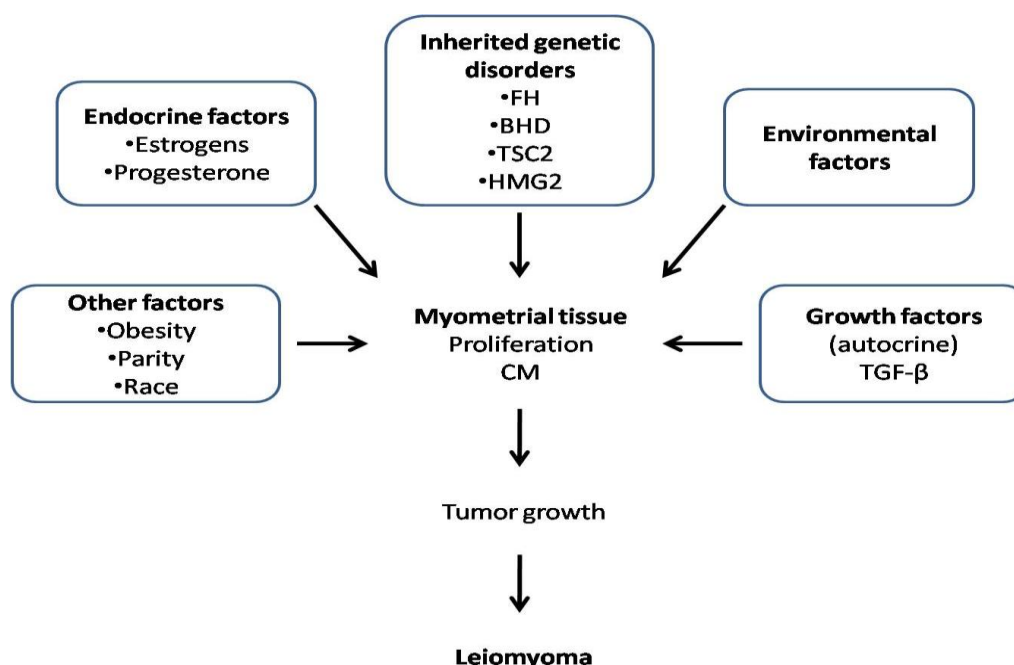


Figure 1. Etiology of leiomyomas is heterogeneous. The genetic defects in the genes and genetic FH, BHD and TSC2 and somatic alterations affecting genes contribute to developing HMG2A leiomyomas, and other risk factors such as obesity, parity and ethnicity. Tumor growth is caused by tumor cell proliferation and production of extracellular matrix (CM) caused by endocrine factors (estrogen and progesterone) and an autocrine growth factors including transforming growth factor beta (TGF-β).

Estrogen and progesterone plays an important role in tumor biology LM; blacks having increased incidence of polymorphisms in the estrogen receptor α (ER- α) ^[18]. Have been recently identified molecular alterations responsible for their growth and greater prevalence. Most LM (60%) are chromosomally normal and 40% present karyotype or chromosomal rearrangements predominantly several common specific karyotypes are associated with uterine size and location; there are also differences in the genetic profiles. Specific cytogenetic abnormalities, including translocations between chromosomes 12 and 14, Trisomy 12, translocations between chromosomes 6 and 10 and deletions in chromosomes 3 and 7, the translocation (12:14) is the most common cytogenetic abnormality (20%). The presence of the gene HMGA2 encoding a high mobility group protein-DNA binding and proliferation modulator that is not expressed in accordance myometrium of patients and is involved in the proliferation of other phenotypes. HMGA2 antagonism of in vitro cellular senescence led LM and decreased proliferation ^[19,20]. The chromosomally abnormal LM generally are larger and submucosal ^[21]; also part of hereditary cancer syndromes, such as hereditary syndrome leiomyomatosis and renal cell cancer (HLRCC), an autosomal dominant syndrome that predisposes LM benign skin and uterus early or early development of renal papillary carcinoma, and this gene, fumarate hydratase (FH), causing increased risk of uterine sarcomas, encoding the enzyme of the Krebs cycle responsible for the conversion of fumarate to malate, and screening is indicated family ^[7,21].

Another LM syndrome is associated with Alport syndrome, a progressive nephropathy and its most common cause of heredity transmission is linked to the X chromosome, this syndrome is associated with LM due to defects in the genes COL4A5 and COL 4A6 ^[21]. Current sequencing technologies allow genome screening studies to identify genes associated with susceptibility to LM ^[22]; three loci have been identified in these individuals' genotypes: 10q24.33, 22q13.1 and 11p15.5. The

chromosome 10q24.33 is the largest association with these and mapping in the 5' region of the gene encoding SLK STE20-like kinase. The STE20-like kinase is expressed in proliferating myoblastic and is activated by epithelial alterations. The ETS-20-like kinase plays a role in myogenic differentiation, cell motility and activated with injuries or wounds ^[23].

Another product of the gene located in the region of the A-kinase anchor protein 13 (AKAP13). A protein kinase is an anchor 13 which is associated with cytoskeletal filaments of LM cells. These cells respond poorly to mechanical stress and are accompanied by the abnormal deposition of extracellular matrix (CM) ^[24]. Deregulation in these processes through mutation is responsible for the LM fibrotic phenotype.

Common mutations occur in LM, 70% are in the mediator complex subunit 12 (MED12), a transcriptional regulator. These co-activator complexes interact directly with the role of estrogen receptors (ER) α and β and improve ER function in vitro, explaining the increased growth of LM.

Microarrays genetic studies indicate that LM is a fibrotic disease and genes involved in fibrosis, and ECM production and maintenance is altered gene expression between LM and myometrium which represents 30% ^[27]. In the etiology of abnormal ECM LM involves transforming growth factor- β (TGF- β), a growth factor in profibrotic activity and TGF- β 3 which is the major isoform expressed in the female reproductive tract and their receptors are found in LM and normal myometrium ^[28-32]. TGF β 3 and the signaling molecules in the LM is overexpressed compared to the myometrium. Epigenetic changes have also been implicated in its formation. The hypo-methylation in the ER- α and the overall genomic methylation abnormal in LM compared with the myometrium involves epigenetic contributions to genetic susceptibility for development ^[23,28-32].

Myometrial injury initiates a cascade of changes in growth factors, causing cell proliferation and increased apoptosis lower CM production where the TGF- β is a key mediator in this system fibrosis

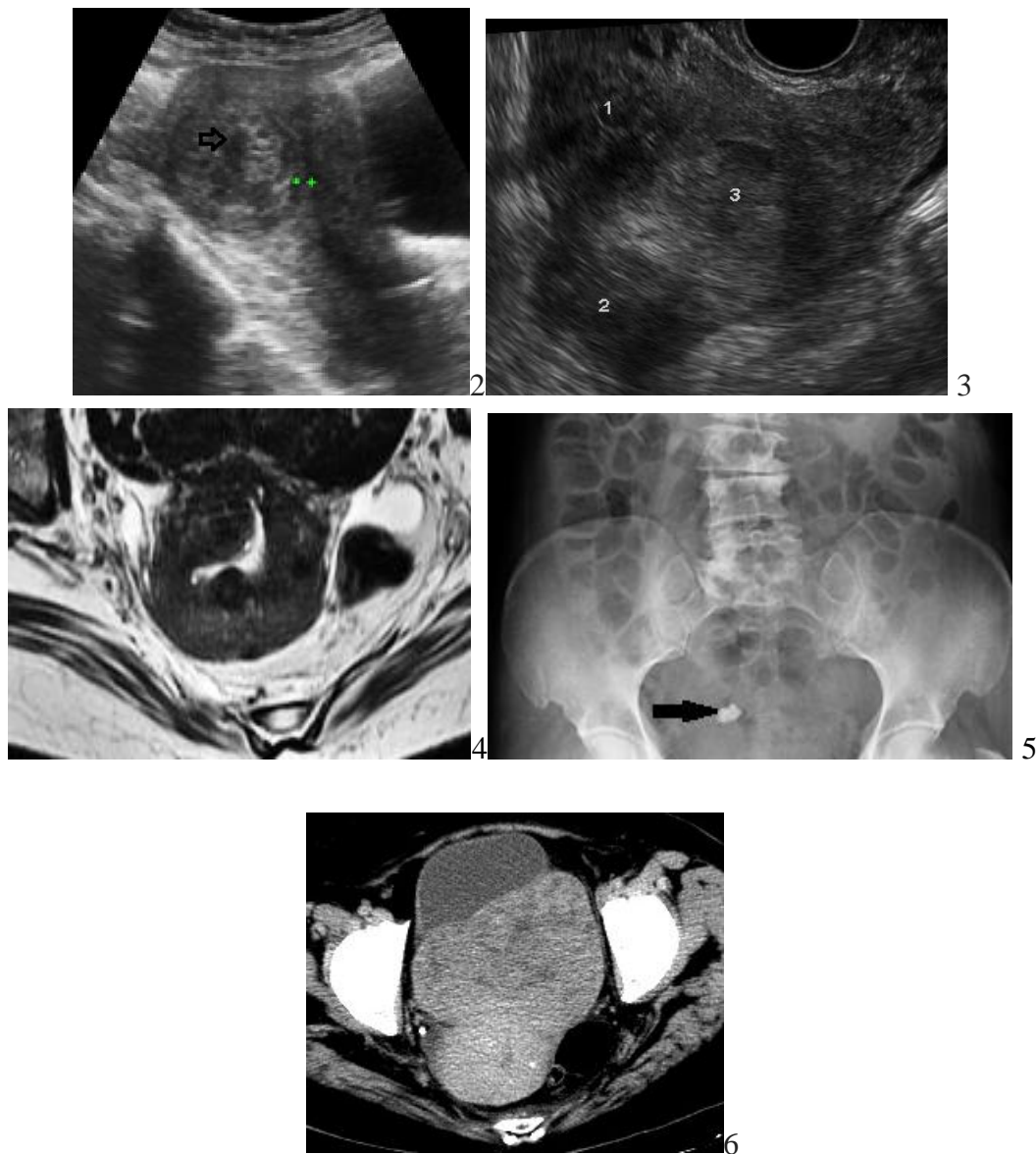
in these tumors are called fibroids emphasizes the importance of the CM in these tumors ^[9]. Growth factor deregulation angiogenesis and fibroblast growth factor are the many key via LM. Microarray analyzes have reported that 25% of the differentially expressed genes between the myometrium and LM are involved in the transformation of the signaling of the TGF- β , collagen, and ^[33,34] CM production. Knowledge about the molecular causes of common mutations involving LM that relate to their development help the preventive management with specific inhibitors.

IMAGING IN LEIOMYOMAS

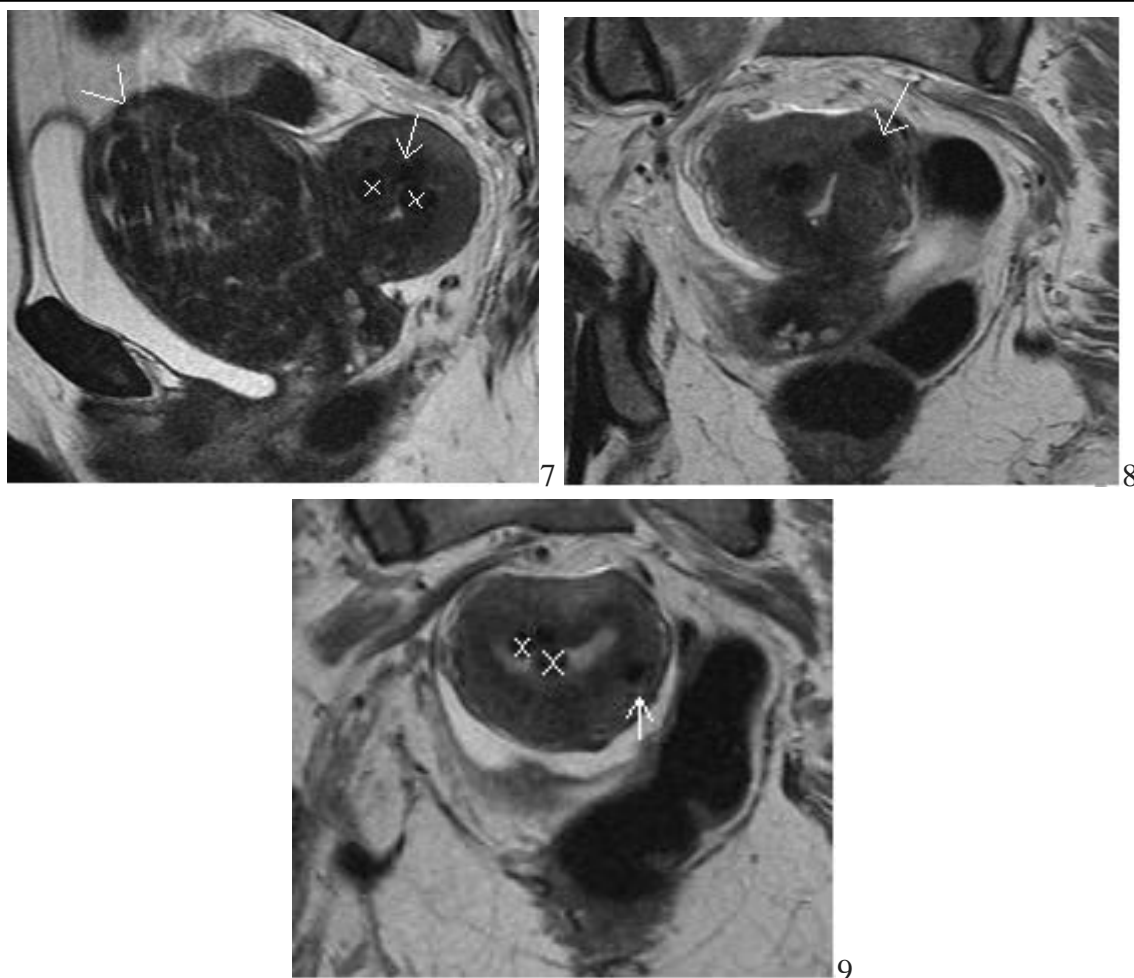
Imaging modalities for the evaluation of LM are the US, transabdominal and transvaginal, magnetic resonance imaging (MRI) of the pelvis radiographs and computed tomography (CT) ^[2,4,7,35]. The US is the preferred imaging method for detecting and evaluating LM, most are intramural, located in the myometrium or are submucosal and subserosal are concentric or as solid masses hypoechoic, absorbing sound waves and cause shadow sound, which varies in its degree of echogenicity, heterogeneous or hyperechogenic, depending on the amount of fibrous tissue and / or calcification also have components resulting from necrosis anechoic, the lower uterine segment LM obstructing the canal, the band moving echogenic endometrial. Calcifications are hyperechoic with acoustic shadowing with sharp and diffuse enlarged uterus with abnormal echogenicity, the US has a sensitivity of 60%, specificity 99% and accuracy of 87%. The US appearance of LM diagnosis usually, 5% (especially when they suffer necrosis) simulate normal pelvic structures (particularly ovaries) and pelvic pathologic changes, uterine abnormalities and pregnancy-related conditions, where the RM clarify US findings of the pelvis ^[2, 35].

MRI has an important role in defining the anatomy of the uterus and ovaries, as well as the assessment of their pathology when the results of other studies are unclear, it is useful for

myomectomy, MRI contrast generally not required, although improve the image of these, are hypointense (65%), isointense (23%) and hyperintense (12%) compared with the image of the myometrium. The main limitation of MRI is the high cost, availability, and is contraindicated in patients with pacemakers or metallic foreign bodies, claustrophobia is relative sensitivity is 86-92%, specificity 100% and accuracy 97%. Conventional radiographs have a limited role in the diagnosis and only calcified LM are identified and large seen as nonspecific soft tissue mass in the pelvis that displaces bowel loops. Like radiography, CT has a limited role and only the LM often distinguished from healthy myometrium when calcified or necrotic, see figures 2-6.



Figures 2,3,4,5,6. Assessment of uterine leiomyomas (LM) 1. Transabdominal ultrasound, LM with cystic degeneration, round, heterogeneous, with internal necrosis (hollow arrow) anechoic areas. 2. Transvaginal ultrasound provides further guidance on the quantity, location and the type of degeneration of the LM. (Designated with number 1) intramural LM which does not deform the endometrial cavity or the edges of the uterus, submucosal LM (number 2), observe as it displaces the endometrium (arrow) and submucosal myoma (number 3) that modifies the edges of the uterus) 3. MRI-T2 with multiple LM which are rounded images of low signal strength, some with areas of greater intensity or lower according to the contents of fibrous tissue or type of necrosis 4. X-ray of abdomen, shows (arrow) irregular and radiopaque calcification feature of fibroids with degeneration calcium 5. CT scan shows the LM of variable density usually hypodense in comparison to the normal myometrium.



Figures 7,8,9. Location of the LM MRI T2, a 48-year-old woman. Submucosal sagittal section, figure 7, intramural coronal section, figure 8 and subserosal coronal section, figure 9

PERINATAL COMPLICATIONS ASSOCIATED UTERINE LEIOMYOMAS

Pregnant women during prenatal care in the first quarter, the US shows that its prevalence of LM during pregnancy is 10-20% [36]. Abdominal pain is the most common complication during pregnancy (15%) and are involved with perinatal complications, spontaneous abortion and 22% diagnosed by U.S. in the first quarter is twice that pregnancy loss compared with controls (14% vs. to 7.6%), also in patients with ART use in vitro fertilization (IVF) than controls (15.3% vs. 7.7%) myomectomy reduces the incidence of early spontaneous abortion from 36% to 60% [2,7,13,14].

Women with LM have higher rates of caesarean sections than women without LM (48.8% versus 13.3%) associated with antepartum complications, increased incidence of fetal malpresentation, abnormal placentation and obstructed labor, the decision of birth should be individualized

depending on the size, location, obstetric history and smaller LM located in the uterine segment caesarean section have an increased of risk [13,14].

The most common neonatal morbidity associated with preterm LM is mainly in large (> 5cm), a short cervical length (<2.5 cm) in pregnancies ≤ 32 weeks, is a marker of premature birth and is associated with the presence of LM [37,38].

The abnormal placentation is associated with placental abruption and is related to LM retroplacental (OR 2.1, 95% CI 1.4 to 3.0), women with LM are at increased risk of placenta previa (OR 2.2, CI 95% 1.5 to 3.2) and intrauterine growth restriction (IUGR) (OR 2.5, 95% CI 1.2-5.0) [36-38].

MANAGEMENT LEIOMYOMAS

Treatment of LM worldwide vary widely, due to differences in factors such as health systems, cultural, personal preferences and medical

treatment is the most variable (55.8 to 18.5%), the options treatment are: observation, medical treatment, and surgical: myomectomy, uterine artery embolization, MRI and hysterectomy mainly. Technological advances in minimally invasive surgery, interventional imaging, new drugs, allow alternatives for prevention of these tumors, including retinoic acid, antifibrotic drug pirfenidone, green tea components^[10] and vitamin D, which are aimed at initial symptoms, but there is little information^[2,7,11,12,39]. Genetic susceptibility to LM by analytical study of the genome and a better understanding of the natural history of the disease have replaced traditional treatment. 77% of women who choose single observation are not harmed and no significant change and this watchful waiting is considered mainly during the last years of the transition to menopause, because after menopause, the decrease in size LM 3; women do not require surgical treatment even if growth is rapid, but they affect quality of life are treated according to the desire of the patient and severity of symptoms^[2,7,27].

SURGICAL TREATMENT

Surgical procedures include myomectomy, endometrial ablation, or hysterectomy. however, the management depends on the age of the woman, desire for future fertility, reproductive and obstetric history, location, number and size of these. In most countries, more than half the women were performing surgery and hysterectomy is the main type of surgery^[40,41], followed by myomectomy, the percentage of women who had undergone hysterectomy is times higher when are diagnosed with LM compared with women without a diagnosis^[5,17]. Serious medical conditions, severe anemia or ureteral obstruction, symptoms that compromise quality of life, bleeding, pain, pelvic and incontinence pezones are also indications for surgery and myomectomy improves symptoms in 80%^[44,41]. Myomectomy by different surgical approaches is the standard therapy in women without parity satisfied of reproductive age for submucosal LM

is performed via hysteroscopy surgery, in intramural or subserosal LM Laparoscopy track especially when they are less than; also by laparotomy with microsurgical technique is indicated, however, the prior assessment of leiomyoma number, size and location are necessary for the selection of surgical approach^[2,3,7].

LM in infertile patients with more than 50% achieved spontaneous pregnancy after open or laparoscopic myomectomy. LM submucosal managing hysteroscopy surgery or laparotomy treated compared with untreated control groups who were LM performed autologous IVF or oocyte donor recipients, autologous IVF and oocyte donation the clinical pregnancy was similar in both. LM Patients with large (> 5cm) on ART before myomectomy demonstrated improved live birth rates (21% vs 10%, $p < 0.05$) compared with those who were not performed myomectomy, another report shows benefit of myomectomy before ART, indicating that myomectomy for submucosalleiomyomas before ART is beneficial and intramural leiomyomas > 5cm also 50% improvement the live birth rate^[2,7,20].

Hysteroscopic myomectomy and endometrial ablation. LM submucosal causing miscarriage HUA and hysteroscopic are removed, improving the quality of life and pregnancy rate, reduces HUA 82% for submucosal pedunculated LM (type 0), 86% in LM sessile (type 1) and 68% for LM intramural (type 2) and one additional surgery was reported in 9.5% at 2 years, 10.8% at 5 years and 26.7% at 8 years^[11,18-23].

Endometrial ablation, with or without hysteroscopic myomectomy, also seen in women with parity satisfied; improve the HUA, 1-5 years 94% and 12% required hysterectomy; hydrothermal ablation of 91% improved after one year HUA follow-up, women with submucosal LM HUA and type 1 or 2 to 3 cm in size, treatment with NovaSure® endometrial ablation improved 95% at 1 year follow up from^[11,18-23]. Abdominal myomectomy; during abdominal myomectomy intraoperative injury risk is lower, the abdominal hysterectomy complications reported 13% (bladder injury, ureteral, bowel,

pelvic abscess and ileus) myomectomy compared with 5% (lesion re bladder and bowel obstruction intervention and ileus) ^[27], other complications such as bleeding, febrile morbidity, unintended surgical procedures, life-threatening events, and rehospitalization did not differ.

This avoids increased bleeding during myomectomy with use of tourniquets or vasoconstrictors (vasopressin) ^[25] and complications are rare as bradycardia and cardiovascular collapse inadvertent intravascular injection, but require careful monitoring. A cellular processor reduces the need for preoperative donation of autologous or heterologous blood for transfusion. This device for aspiration of blood from the operative field, mixed with heparinized saline that stores the blood when the blood loss greater than 300 ml, the blood collected was washed, filtered, centrifuged and administered to the patient. Myomectomy of large tumors in relation to the size of a 16-36 week pregnancy reported occasionally bowel injury, bladder or intestinal obstruction reoperation for, without conversion to hysterectomy ^[2,7,26].

Hysterectomy and laparoscopic myomectomy The indication of laparoscopic myomectomy is limited to the size and number of LM that are reasonably eliminated, technical difficulty of laparoscopic, robotic assisted surgery helps the surgeon to avoid technical problems, but the cost and longer operating time must be considered, when compared with laparotomy, the time is longer, but the blood loss, postoperative pain and complications are minor, and total recovery in two weeks, even in large 15cm LM where scarcely require conversion to laparotomy ^[42-47].

Myolysis by coagulation is not recommended laparoscopically is associated with adhesion formation and possible uterine rupture during pregnancy and is not currently indicated ^[48]. The uterine artery occlusion by laparoscopy in women with LM reported improved symptoms, but the cost-effectiveness compared with embolization of uterine leiomyomas (UFE) requires further studies ^[2,49]. Hysterectomy is the definitive treatment for

the introduction of laparoscopy has led to significant changes and laparoscopic hysterectomy rate increased in the last 2 decades from 0.3 to 11.8% secondary to safety and efficacy, shorter hospital stay, early reintegration to everyday activity, less bleeding and morbidity at lower cost, however, these benefits must be weighed against the increased risk of ureteral damage via laparoscopy learning curve and surgical skills ^[40,41].

Interventional Radiology

Embolization of uterine leiomyomas (UFE) is an effective treatment for LM since 3 decades, especially when symptoms are important to require surgery and has become one of the main maneuvers of these with results comparable to myomectomy or hysterectomy and the complication rate is similar, but the reset and start normal activities is quicker, although the rate of satisfaction is higher with hysterectomy (88%) versus UFE (78%) ^[50].

The technique is channeling through the femoral artery percutaneous embolization for uterine artery and its branches, the radiation exposure is similar to 1-2 TC or barium enema. Management of pain after the procedure usually requires hospitalization for one day, followed by 1-2 weeks of anti-inflammatory drugs. Many women return to normal activities within 1-3 weeks. The decrease in tumor size and the symptoms are 42% and 77-86%, respectively, with women's satisfaction to 3 month follow-up of 91% and 3% required hysterectomy within 8 months after UFE complications 1.5% ^[50]. Women who did not accept the hysterectomy, even for complications not life threatening, should avoid this procedure, even if there is active genital infection, gynecological cancer, immunosuppression, difficulty in access to the uterine arteries for any reason, and contrast allergy impaired renal function. The hospital stay is short (two days compared to 5 days for hysterectomy). Although UFE exceptional complications may require hysterectomy ^[50]. Have lower incidence of major complications at 6 months with 8% risk of

repeating the procedure but is associated with more hospital readmissions for pain or fever (9 vs. 0 for hysterectomy) worldwide, 12 deaths were reported (two septic shock, pulmonary embolism 8 and 2 unknown) associated with over 100,000 UFE procedures, the mortality rate is low UFE 1 in 10,000 compared to 10,000 surgeries 3, at 3 months follow-up, 83% improved HUA, dysmenorrhea, urinary symptoms 77% and 86%, decreased 33%, 30% of the UFE requires treatment to control recurrent symptoms is recommended that women who are considering having full assessment embolization between the gynecologist and interventional radiologist; because the effects of UFE on fertility and pregnancy are not clear and is not recommended if women considering pregnancy in the future^[51-54]. Fertility after UFE is controversial and its safety has not been established; spontaneous pregnancies have been reported in 61% or ART in these women with UFE, spontaneous abortions from 13 to 16.7%, some cases of premature births and placentation abnormal (placenta accreta which required cesarean-hysterectomy and uncomplicated term pregnancies, other reports have shown increased risk of obstetric complications, such as first trimester abortions, fetal malpresentation, abnormal placentation, IUGR and preterm delivery; also report atrophy permanent endometrial and is not recommended for patients without parity satisfied^[52,55,58].

MRI guided high intensity ultrasound

The technique of MRI guided high-intensity ultrasound or MRI-Guided Focused Ultrasound (MRgFUS) is approved for treatment of LM since more than 10 years ago it was reported that 80% is reduced in size, 20 to 30% two years without long-term complications, symptomatology improves 71% at 6 months and 50% after a year of treatment, 28% require myomectomy or hysterectomy and UFE is not recommended for women without parity satisfied, although pregnancies have been achieved at 8 month follow-up with live birth rate of 41% and spontaneous abortion rate of 28%, most with term

pregnancies and 57% of these pregnancies had maternal or perinatal complications, where it is shown reproductive safety and efficacy will be a safe option for the management of LM^[2,7,59,60]. MRgFUS technique is performed with the heat developed by the U.S. focused to denature proteins and cause cell deaths, the RM is directed toward evaluating LM and monitor the temperature of the targeted tissue, the advantages are low morbidity and fast recovery, with return to normal activity in a day with decreased symptoms in 50-71%. As technology continues to develop, more studies are necessary to evaluate the risks and efficacy of MRgFUS because the recurrence rate is high and is associated with side effects such as burn abdominal wall thickness^[53,59,60,61].

Cryotherapy administered MRI guide reduces tumor volume by 65%, range 31% +/- 28%, but the efficacy and safety of these techniques require further study^[62].

MEDICAL TREATMENT

The goal of medical management is to improve symptoms and when surgery is indicated facilitate it and avoid the complications associated mainly intervention if conservative, however, symptoms usually recur after discontinuation of medical treatment and reduces tumor size and improve the clinical condition of the woman, the modulation of growth factors and hormone receptors in smooth muscle cells and vascular system LM^[1] see table 1, the percentage of women who received medical treatment after diagnosis ranged from 18, 5% (95% CI: 12.7-25.4%) to 55.8% (95% CI: 50.7-60.8%)^[39].

TABLE 1

Medical treatment of leiomyomas

- Oral contraceptives
- Progestogens
- Agonist and antagonists of gonadotropin releasing hormone GnRH
- Selective modulators of estrogen or progesterone receptors
- Antiandrogens
- Antiprogestins

Hormonal Contraceptives

Oral Contraceptives (OCs) combined, and the Progestin-only pills are effective for bleeding, but do not influence the natural history of the LM [39]. Administration Medroxyprogesterone Acetate at doses of 150mg each month for 6 months HUA decreases by 30 to 70% and tumor volume temporarily less effective than agonists gonadotropin releasing hormone (GnRH-a) [13,14]. Alternatively the intrauterine or system releasing levonorgestrel (LNG-IUS) in women with one LM 5cm, less than 50% of LM occupying the endometrial cavity (type 2), 90% reduced blood loss by decreasing the amount and duration with increased hemoglobin one years after insertion [39,62]

Gonadotropin releasing hormone (GnRH)

GnRH agonists induce hypoestrogenism that limit the duration of treatment, and LM regrow after interrupt are used before surgery for 3 months, reduce the size and vascularity facilitate surgery and reduce perioperative morbidity associated with myomectomy, corrects anemia, avoiding large incisions and provide surgical alternatives, size reduction is achieved in 30 to 40% in 14 days, are clinically useful in the management of ART. GnRH analogues reduced 35% in size and 95% improvement HUA decreasing the uterine volume, in obese this decrease is lower because hyperestrogenism develop persistent links derived from peripheral aromatization extragonadal by the peripheral conversion of androgens to estrogens. In perimenopausal women develops spontaneous menopause preventing tumor growth, are considered short term and one in 34 is avoided surgery. During hysteroscopy, a single dose the month before the procedure is provided, 95% of women will experience side effects from the hypoestrogenism as hot flashes (78%), vaginal dryness (32%) and headache (55%), with some arthralgia, myalgia, insomnia, edema, emotional lability, depression, or decreased libido, hair loss, discomfort and musculoskeletal stiffness, affecting bone mineral density (BMD) significantly after 6 months of use, low doses of

estrogens and progestins in controversial use to improve BMD. GnRH antagonists compete for binding to GnRH receptors, in contrast to GnRH agonists, their administration is not associated with a phenomenon called immediate stimulation, having a greater effect than the GnRH agonist, but its use is limited for administered daily [39,63].

Modulators Selective Estrogen Receptor (SERM's)

Lols SERM's are a new class of modular estrogen receptor (ER) with effect agonist or antagonist in various tissues including endometrium, are used in the management of HUA decreasing the duration and amount of dose-response using Raloxifene (RLX) in postmenopausal women with LM reduce their size but their clinical use is not relevant [39]. Other medical treatment with selective modulators of progesterone receptors (PR) or Selective progesterone receptor modulators (SPRM) is being evaluated. Antiprogesterin mifepristone (RU-486), is a synthetic steroid derived from norethindrone having antiprogesterin and antiglucocorticoid effect endometrium level, exerts anti-estrogenic effects and has been used in doses of 5 to 50mg per day for 3 months with symptom causing secondary amenorrhea vasomotor, decreases serum levels of follicle stimulating hormone (FSH), temporarily increases luteinizing hormone (LH) and androstenedione, progesterone decreases, without changes in the levels of Estradiol and Estrone, dehydroepiandrosterone sulfate, sometimes causes dyslipidemia and does not affect bone mineral density (BMD). Menstrual cycles are reset to 3-6 weeks stopping and tumor shrinkage in 26-50%, improves anemic state, the side effects are less than those caused by hypoestrogenism when compared to a-GnRH. Mifepristone was effective in reducing the size and associated symptoms; during follow-up after six months of treatment, the effects continued for a year [39]. SPRM treatment as asoprisnil also reduced the size and improved the dose-response HUA, and UPA (CDB-2914) is approved as an emergency contraceptive and shown to decrease the volume of the LM with

5mg orally per day during 13 weeks of treatment and induces amenorrhea HUA improves by 90% and the quality of life after 12 weeks of treatment and control of bleeding by 98% at doses of 10 mg per day two weeks achieving amenorrhea with faster compado leuprolide acetate and a lower incidence of side effects in 24% compared to placebo; uterine volume reduction was maintained for 6 months after discontinuation of ^[39,64-72].

One benefit of SPRMs compared with GnRH analogs is the absence of hypoestrogenic side effects, such as decreased bone mineral density and hot flashes, maintaining estradiol levels during use ^[39]. The main risk with SPRMs is the long-term effect on the endometrium, by blocking the action of progesterone on the endometrium and inhibit ovulation, providing a persistent estrogenism unopposed and increased risk of endometrial changes that are different from endometrial hyperplasia called endometrial changes associated with progesterone (PAEC), but increases the incidence of endometrial hyperplasia without atypia in 63.1% when administered at a dose of 10mg per day for 3 months ¹⁶; without data atypical hyperplasia returns after PAEC of 3-6 months after stopping treatment, but the natural history of PAEC as well as the safety of long-term SPRMs PAEC has not been established ^[39,73-76].

Therapeutic success of the blockade of progesterone is based on clinical data, but has not been verified by the administration of progesterone receptor modulators in August even steroid hormonal control has provided therapeutic effect in LM ^[39].

Aromatase inhibitors (AI); the AI inhibit the conversion of androgens to estrogens and reduce levels of estrogen and the administration of letrozole for 2 months decreased tumor volume by 71% at doses of 2.5mg in handling leiomyomas > 5cm and was superior to GnRH analogue (triptorelin) to reduce its size (45.6% vs. 33.2%) after 12 weeks of treatment, but further studies are needed on the effect, long-term safety and reproductive function after treatment ^[39]. The Gestrinone is androgen derivative ethynyltestosterone properties and anti-

progesterone and anti-estrogenic effects. 5mg administration 3 times a week for 2 months in women with leiomyomas these shrinks 40% in the second month of taking secondary amenorrhea develops but continuous administration two times a week for 1 year, but androgenic side effects (acne, hirsutism, seborrhea), and weight gain symptoms recur by suspending ^[39,78]. The Danazol is a derivative of 17-alpha-ethinyl testosterone, which has multiple effects at different levels of the hypothalamic-pituitary-ovary through binding to intracellular estrogen receptors, androgen, progesterone and glucocorticoid, the use in patients with LM reduced in volume by 23.6% and decrease HUA, however, important side effects such as hyperandrogenism (acne, hirsutism) and weight gain, that limit their clinical application ^[39].

Complementary and Alternative Medicine

Most published studies on alternative medicine treatments are controversial non-randomized, unblinded and small. One study reported that after 6 months of treatment with traditional Chinese medicine, the LM was reduced by U.S. 59% compared with 8% of controls and LM under 10cm, the HUA was reduced 95% and dysmenorrhea improved 94% ^[78,79].

FUTURE MANAGEMENT LEIOMYOMAS

Medical treatment is aimed at future cell differentiation pathways. The excess LM tumors are abnormal in CM production and modulation of this process provides its control. Inhibitors of TGF- β pathway avoids the production of CM proteins and reduction in rats LM; also down-regulation in the pathway of TGF- β decreases the messenger RNA expression of multiple genes in the CM LM and therapy directed at disruption of this process will be therapeutic fibrotic ^[29,30].

The LM possess a pathway through retinoic acid and retinoids modulate these pathways responsible for cell proliferation, apoptosis and survival of these. Decreased endogenous retinoic acid and abnormal production of CM in handling LM retinoic acid transforms CM phenotype to

simulate closely the myometrium by decreased expression of collagens and proteoglycans of the CM through compounds that increase the endogenous retinoic acid fibroids as liarozole (an agent that blocks the metabolism of retinoic acid) with therapeutic potential by inhibiting the formation of abnormal CM through via retinoic acid without retinoic acid pathway without significant side effects ^[30,80]. Other promising therapeutic agents are nutritional supplements. Curcumin, with antineoplastic activity, inhibits cell proliferation and reduces the expression of proteoglycans in the CM of LM, green tea extract inhibits cell proliferation in vitro LM. The advantage of these new agents is their low side effects as preventive and therapeutic efficacy over time. Since prevention of the disease is higher and more profitable than treatment, identification of women with risk factors identified LM genetic screening who require preventative treatment, curcumin or green tea extract, slow cell proliferation and abnormal discharge ECM developed in LM ^[81,82].

CONCLUSIONS

The uterine LM are common in women of reproductive age and most do not require treatment because they are benign, is a heterogeneous disease and recent advances on its origin and pathogenesis by molecular alterations, will adapt specific mechanism responsible for its management. The knowledge of tumor biology can provide medical and surgical treatments that improve symptoms and morbidity, the development of new drugs and less invasive procedures can be avoided even conservative hysterectomy surgery when the response is adequate, preserving fertility for achieving pregnancy and avoid losing them affects tumor growth and digestive tract functions causing obstructive syndromes, hysterectomy is the last treatment when no response to conservative management and the symptoms interfere with quality of life.

REFERENCES

1. Laughlin SK, Schroeder JC, Baird DD. New directions in the epidemiology of uterine fibroids. *SeminReprod Med.* 2010;28:204–17.
2. Zimmermann A, Bernuit D, GerlingerCh, Schaefer M, Geppert K. Prevalence, Symptoms and Management of Uterine Fibroids An International Internet-based Survey of 21,746 Women *BMC Womens Health.* 2012;12(6).
3. Cardozo ER, Clark AD, Banks NK, Henne MB, Stegmann BJ, Segars JH. The estimated annual cost of uterine leiomyomata in the United States. *Am J Obstet Gynecol.* 2012;206:211. e1–9.
4. Okolo S. Incidence, aetiology and epidemiology of uterine fibroids. *Best Pract Res ClinObstetGynaecol.* 2008;22:571–88.
5. Ishikawa H, Reierstad S, Demura M, Rademaker AW, Kasai T, Inoue M, et al. High aromatase expression in uterine leiomyoma tissues of African-American women. *J ClinEndocrinolMetab.* 2009;94:1752–6.
6. Peddada SD, Laughlin SK, Miner K, et al. Growth of uterine leiomyomata among premenopausal black and white women. *Proc Natl AcadSci U S A.* 2008;105:19887-19892.
7. Gary Levy^{1, 2}, Micah J. Hill¹, Stephanie Beall¹, Shvetha M. Zarek¹, James H. Segars¹ and William H. Catherino² Leiomyoma genetics, assisted reproduction, pregnancy and therapeutic advances. *J Assist ReprodGenetics* 2012;29 (8):703-712
8. Sahagún-Quevedo JA, Vargas-Hernandez VM. Leiomiomatosis uterina e infertilidad, en Vargas-Hernández VM, editor. *Histerectomíaindicaciones, complicaciones y alternativas México: DEMSA; 2005, pp 253-258.*
9. Nelli E, Tinelli R, Colafiglio G, Saliani N. Laparoscopy vs Minilaparotomy in women with symptomatic uterine miomas: A

- Prospective Randomized study. *J Minim Invas Gynecol* 2009;16(4):422-426.
10. Horcajadas JA, Goyri E, Higon MA, Martinez-Conejero JA, Gambadauro P, Garcia G, et al. Endometrial receptivity and implantation are not affected by the presence of uterine intramural leiomyomas: a clinical and functional genomics analysis. *J Clin Endocrinol Metab*. 2008;93:3490–8.
 11. Pritts EA, Parker WH, Olive DL. Fibroids and infertility: an updated systematic review of the evidence. *Fertil Steril*. 2009;91:1215–23.
 12. Sunkara SK, Khairy M, El-Toukhy T, Khalaf Y, Coomarasamy A. The effect of intramural fibroids without uterine cavity involvement on the outcome of IVF treatment: a systematic review and meta-analysis. *Hum Reprod*. 2010;25:418–29.
 13. Somigliana E, De Benedictis S, Vercellini P, Nicolosi AE, Benaglia L, Scarduelli C, et al. Fibroids not encroaching the endometrial cavity and IVF success rate: a prospective study. *Hum Reprod*. 2011;26:834–9.
 14. Klatsky PC, Tran ND, Caughey AB, Fujimoto VY. Fibroids and reproductive outcomes: a systematic literature review from conception to delivery. *Am J Obstet Gynecol*. 2008;198:357–66.
 15. Cook H, Ezzati M, Segars JH, McCarthy K. The impact of uterine leiomyomas on reproductive outcomes. *Minerva Ginecol*. 2010;62:225–36. PubMed
 16. Bosteels J, Weyers S, Puttemans P, Panayotidis C, Van Herendael B, Gomel V, et al. The effectiveness of hysteroscopy in improving pregnancy rates in subfertile women without other gynaecological symptoms: a systematic review. *Hum Reprod Update*. 2010;16:1–11.
 17. Bowden W, Skorupski J, Kovanci E, Rajkovic A. Detection of novel copy number variants in uterine leiomyomas using high-resolution SNP arrays. *Mol Hum Reprod*. 2009;15:563–8.
 18. Pan Q, Luo X, Chegini N. Genomic and proteomic profiling I: leiomyomas in African Americans and Caucasians. *Reprod Biol Endocrinol*. 2007;5:34.
 19. Hodge JC, Cuenco KT, Huyck KL, Somasundaram P, Panhuysen CI, Stewart EA, et al. Uterine leiomyomata and decreased height: a common HMGA2 predisposition allele. *Hum Genet*. 2009;125:257–63.
 20. Markowski DN, Helmke BM, Belge G, Nimzyk R, Bartnitzke S, Deichert U, et al. HMGA2 and p14Arf: major roles in cellular senescence of fibroids and therapeutic implications. *Anticancer Res*. 2011;31:753–61.
 21. Uliana V, Marcocci E, Mucciolo M, Meloni I, Izzi C, Manno C, et al. Alport syndrome and leiomyomatosis: the first deletion extending beyond COL4A6 intron 2. *Pediatr Nephrol*. 2011;26:717–24.
 22. Negrin-Perez MC, Fisiopatología de la Leiomiomatosis uterina en Vargas-Hernández VM, editor. *Histerectomía indicaciones, complicaciones y alternativas México: DEMSA*; 2005, pp 231-252.
 23. Cha PC, Takahashi A, Hosono N, Low SK, Kamatani N, Kubo M, et al. A genome-wide association study identifies three loci associated with susceptibility to uterine fibroids. *Nat Genet*. 2011;43:447–50.
 24. Rogers R, Norian J, Malik M, Christman G, Abu-Asab M, Chen F, et al. Mechanical homeostasis is altered in uterine leiomyoma. *Am J Obstet Gynecol*. 2008;198:474. e1–11.
 25. Makinen N, Mehine M, Tolvanen J, Kaasinen E, Li Y, Lehtonen HJ, et al. MED12, the mediator complex subunit 12 gene, is mutated at high frequency in uterine leiomyomas. *Science*. 2011;334:252–5.

26. Chegini N. Proinflammatory and profibrotic mediators: principal effectors of leiomyoma development as a fibrotic disorder. *SeminReprod Med.* 2010;28:180–203.
27. Malik M, Norian J, McCarthy-Kelth D, Britten J, Catherino WH. Why leiomyomas are called fibroids: the central role of extracellular matrix in symptomatic women. *SeminReprod Med.* 2010;28:169–79.
28. Norian JM, Malik M, Parker CY, Joseph D, Leppert PC, Segars JH, et al. Transforming growth factor beta3 regulates the versican variants in the extracellular matrix-rich uterine leiomyomas. *Reprod Sci.* 2009;16:1153–64.
29. Joseph DS, Malik M, Nurudeen S, Catherino WH. Myometrial cells undergo fibrotic transformation under the influence of transforming growth factor beta-3. *FertilSteril.* 2010;93:1500–8.
30. Malik M, Webb J, Catherino WH. Retinoic acid treatment of human leiomyoma cells transformed the cell phenotype to one strongly resembling myometrial cells. *ClinEndocrinol (Oxf).* 2008;69:462–70.
31. Asada H, Yamagata Y, Taketani T, Matsuoka A, Tamura H, Hattori N, et al. Potential link between estrogen receptor-alpha gene hypomethylation and uterine fibroid formation. *Mol HumReprod.* 2008;14:539–45.
32. Yamagata Y, Maekawa R, Asada H, Taketani T, Tamura I, Tamura H, et al. Aberrant DNA methylation status in human uterine leiomyoma. *Mol Hum Reprod.* 2009;15:259–67.
33. Laughlin SK, Herring AH, Savitz DA, Olshan AF, Fielding JR, Hartmann KE, et al. Pregnancy-related fibroid reduction. *FertilSteril* 2010;94(6):2421-2423
34. Yoshida S, Ohara N, XuQ, Chen W, Wang J, Nakabayashi K, et al. Cell-type specific actions of progesterone receptor modulators in the regulation of uterine leiomyoma growth. *SeminReprod Med* 2010;28:260-273
35. Sánchez-Conde RM. Resonancia Magnética en la patología benigna de útero y ovarios en Vargas-Hernández VM, editor. *Histerectomía: indicaciones, complicaciones y alternativas México: DEMSA; 2005, pp 29-40*
36. Laughlin SK, Baird DD, Savitz DA, Herring AH, Hartmann KE. Prevalence of uterine leiomyomas in the first trimester of pregnancy: an ultrasound-screening study. *Obstet Gynecol.* 2009;113:630–5.
37. Shavell VI, Thakur M, Sawant A, Kruger ML, Jones TB, Singh M, et al. Adverse obstetric outcomes associated with sonographically identified large uterine fibroids. *FertilSteril.* 2012;97:107–10.
38. Stout MJ, Odibo AO, Graseck AS, Macones GA, Crane JP, Cahill AG. Leiomyomas at routine second-trimester ultrasound examination and adverse obstetric outcomes. *ObstetGynecol.* 2010;116:1056–63.
39. Vargas-Hernández VM, Tovar RJM, Moran VC, Moctezuma EJ. Tratamiento médico de Leiomiomatosis en Vargas-Hernández HVM, editor. *Histerectomía: indicaciones, complicaciones y alternativas México: DEMSA; 2005, pp 315-326.*
40. Drahonovsky J, Feyereisl J. A prospective randomized comparison of vaginal hysterectomy, laparoscopically assisted vaginal hysterectomy, and total laparoscopic hysterectomy in women with benign uterine disease. *Eur J ObstetGynecolReprodBiol,* 2010;148(2):172-176.
41. Jacoby VL, Autry A, Jacobson G, et al. Nationwide Use of Laparoscopic Hysterectomy Compared With Abdominal and Vaginal Approaches. *ObstetGynecol* 2009;114:1041-1048.
42. Emanuel MH, Wamsteker K, Hart AA, Metz G, Lammes FB. Long-term results of

- hysteroscopic myomectomy for abnormal uterine bleeding. *Obstet Gynecol.* 1999;93(5 Pt 1):743-748.
43. Glasser MH, Zimmerman JD. The HydroThermAblator system for management of menorrhagia in women with submucous myomas: 12- to 20-month follow-up. *J Am Assoc Gynecol Laparosc.* 2003;10:521-527.
 44. Sabbah R, Desaulniers G. Use of the NovaSure Impedance Controlled Endometrial Ablation System in patients with intracavitary disease: 12-month follow-up results of a prospective, single-arm clinical study. *J Minim Invasive Gynecol.* 2006;13:467-471.
 45. West S, Ruiz R, Parker WH. Abdominal myomectomy in women with very large uterine size. *Fertil Steril.* 2006;85:36-39.
 46. Jin C, Hu Y, Chen X, et al. Laparoscopic versus open myomectomy -- a meta-analysis of randomized controlled trials. *Eur J Obstet Gynecol Reprod Biol.* 2009;145:14-21.
 47. Andrei B, Crovini G, Rosi A. Uterine myomas: pelviscopic treatment. *Clin Exp Obstet Gynecol.* 1999;26:44-46.
 48. Hinojosa CJC. Miolisis en Leiomiomatosis uterina en Vargas-Hernández VM, editor. *Histerectomía indicaciones, complicaciones y alternativas México: DEMSA; 2005, pp 309-314.*
 49. Brill AI. Treatment of fibroids via uterine artery occlusion (uterine artery embolization and Doppler-guided uterine artery occlusion): potential role in today's armamentarium. *Arch Gynecol Obstet.* 2009;280(4):513-521.
 50. Cano-Muñoz I. Tratamiento endovascular mediante embolización en Vargas-Hernández VM, editor. *Histerectomía indicaciones, complicaciones y alternativas México: DEMSA; 2005, pp 295-307.*
 51. Moss JG, Cooper KG, Khaund A, Murray LS, Murray GD, Wu O, et al. Randomised comparison of uterine artery embolisation (UAE) with surgical treatment in patients with symptomatic uterine fibroids (REST trial): 5-year results. *BJOG.* 2011;118:936-44.
 52. American Society of Reproductive Medicine (ASRM). Myomas and reproductive function. *Fertil Steril.* 2008;90:S125-S30.
 53. Hehenkamp WJ, Volkers NA, Donderwinkel PF, et al. Uterine artery embolization versus hysterectomy in the treatment of symptomatic uterine fibroids (EMMY trial): peri- and postprocedural results from a randomized controlled trial. *Am J Obstet Gynecol.* 2005;193:1618-1629.
 54. Committee on Gynecologic Practice, American College of Obstetricians and Gynecologists. ACOG Committee Opinion. Uterine artery embolization. *Obstet Gynecol.* 2004;103:403-404.
 55. Goldberg J. Pregnancy after uterine artery embolization for leiomyomata: the Ontario Multicenter Trial. *Obstet Gynecol.* 2005;106:195-6.
 56. Firouznia K, Ghanaati H, Sanaati M, Jalali AH, Shakiba M. Pregnancy after uterine artery embolization for symptomatic fibroids: a series of 15 pregnancies. *Am J Roentgenol.* 2009;192:1588-92.
 57. Homer H, Saridogan E. Uterine artery embolization for fibroids is associated with an increased risk of miscarriage. *Fertil Steril.* 2010;94:324-30.
 58. Holub Z, Mara M, Kuzel D, Jabor A, Maskova J, Eim J. Pregnancy outcomes after uterine artery occlusion: prospective multicentric study. *Fertil Steril.* 2008;90:1886-91.
 59. Kim HS, Baik JH, Pham LD, Jacobs MA. MR-guided high-intensity focused ultrasound treatment for symptomatic uterine leiomyomata: long-term outcomes. *Acad Radiol.* 2011;18:970-6.
 60. Rabinovici J, David M, Fukunishi H, Morita Y, Gostout BS, Stewart EA, et al.

- Pregnancy outcome after magnetic resonance-guided focused ultrasound surgery (MRgFUS) for conservative treatment of uterine fibroids. *FertilSteril*. 2010;93:199–209.
61. LeBlang SD, Hocter K, Steinberg FL. Leiomyoma shrinkage after MRI-guided focused ultrasound treatment: report of 80 patients. *AJR Am J Roentgenol*. 2010;194:274–280.
 62. Machado RB, de Souza IM, Beltrame A, Bernardes CR, Morimoto MS, Santana N. The levonorgestrel-releasing intrauterine system: its effect on the number of hysterectomies performed in perimenopausal women with uterine fibroids. *GynecolEndocrinol*. 2013;29(5):492–5.
 63. Tropeano G, Amoroso S, Scambia G. Non-surgical management of uterine fibroids. *Hum Reprod Update*. 2008;14:259–74.
 64. Croxtall JD. Ulipristal acetate: in uterine fibroids. *Drugs*. 2012;72:1075–1085.
 65. Feng C, Meldrum S, Fiscella K. Improved quality of life is partly explained by fewer symptoms after treatment of fibroids with mifepristone. *Int J Gynaecol Obstet*. 2010;109:121–4.
 66. Engman M, Granberg S, Williams AR, Meng CX, Lalitkumar PG, Gemzell-Danielsson K. Mifepristone for treatment of uterine leiomyoma. A prospective randomized placebo controlled trial. *Hum Reprod*. 2009;24:1870–9.
 67. Bagaria M, Suneja A, Vaid NB, Guleria K, Mishra K. Low-dose mifepristone in treatment of uterine leiomyoma: a randomised double-blind placebo-controlled clinical trial. *Aust N Z J ObstetGynaecol*. 2009;49:77–83.
 68. Esteve JL, Acosta R, Perez Y, Campos R, Hernandez AV, Texido CS. Treatment of uterine myoma with 5 or 10 mg mifepristone daily during 6 months, post-treatment evolution over 12 months: double-blind randomised clinical trial. *Eur J ObstetGynecolReprod Biol*. 2012;161:202–8.
 69. Levens ED, Potlog-Nahari C, Armstrong AY, Wesley R, Premkumar A, Blithe DL, et al. CDB-2914 for uterine leiomyomata treatment: a randomized controlled trial. *Obstet Gynecol*. 2008;111:1129–36.
 70. Nieman LK, Blocker W, Nansel T, Mahoney S, Reynolds J, Blithe D, et al. Efficacy and tolerability of CDB-2914 treatment for symptomatic uterine fibroids: a randomized, double-blind, placebo-controlled, phase IIb study. *FertilSteril*. 2011;95:767–72. e1–2.
 71. Donnez J, Tomaszewski J, Vazquez F, Bouchard P, Lemieszczuk B, Baro F, et al. Ulipristal acetate versus leuprolide acetate for uterine fibroids. *N Engl J Med*. 2012;366:421–32.
 72. Donnez J, Tatarchuk TF, Bouchard P, Puscasiu L, Zakharenko NF, Ivanova T, et al. Ulipristal acetate versus placebo for fibroid treatment before surgery. *N Engl J Med*. 2012;366:409–20.
 73. Mutter GL, Bergeron C, Deligdisch L, Ferenczy A, Glant M, Merino M, et al. The spectrum of endometrial pathology induced by progesterone receptor modulators. *Mod Pathol*. 2008;21:591–8.
 74. Ioffe OB, Zaino RJ, Mutter GL. Endometrial changes from short-term therapy with CDB-4124, a selective progesterone receptor modulator. *Mod Pathol*. 2009;22:450–9.
 75. Spitz IM. Clinical utility of progesterone receptor modulators and their effect on the endometrium. *CurrOpinObstet Gynecol*. 2009;21:318–24.
 76. Eisinger SH, Fiscella J, Bonfiglio T, Meldrum S, Fiscella K. Open-label study of ultra low-dose mifepristone for the treatment of uterine leiomyomata. *Eur J ObstetGynecolReprod Biol*. 2009;146:215–8.
 77. Parsanezhad ME, Azmoon M, Alborzi S, Rajaeefard A, Zarei A, Kazerooni T, et al.

A randomized, controlled clinical trial comparing the effects of aromatase inhibitor (letrozole) and gonadotropin-releasing hormone agonist (triptorelin) on uterine leiomyoma volume and hormonal status. *FertilSteril*. 2010;93:192–8.

78. Mehl-Madrona L. Complementary medicine treatment of uterine fibroids: a pilot study. *Altern Ther Health Med*. 2002;8:34-36, 38-40, 42, 44-46.
79. Sakamoto S, Yoshino H, Shirahata Y, Shimodairo K, Okamoto R. Pharmacotherapeutic effects of kuei-chih-fu-ling-wan (keishi-bukuryo-gan) on human uterine myomas. *Am J Chin Med*. 1992;20:313-317
80. Ben-Sasson H, Ben-Meir A, Shushan A, Karra L, Rojansky N, Klein BY, et al. All-trans-retinoic acid mediates changes in PI3K and retinoic acid signaling proteins of leiomyomas. *FertilSteril*. 2011;95:2080–6.
81. Malik M, Mendoza M, Payson M, Catherino WH. Curcumin, a nutritional supplement with antineoplastic activity, enhances leiomyoma cell apoptosis and decreases fibronectin expression. *FertilSteril*. 2009;91:2177–84.
82. Zhang D, Al-Hendy M, Richard-Davis G, Montgomery-Rice V, Sharan C, Rajaratnam V, et al. Green tea extract inhibits proliferation of uterine leiomyoma cells in vitro and in nude mice. *Am J Obstet Gynecol*. 2010;202:289.